



THE USE OF ENDYMED 3DEEP FRACTIONAL MULTIPOLAR RADIOFREQUENCY FOR STRETCH MARKS TREATMENT

Valeriu ARDELEANU^{1,2,3}, Cristian Constantin POPA^{4,5}, Dumitru Cristinel BADIU^{4,6}, Anca PANTEA STOIAN⁴, Valentin Titus GRIGOREAN^{4,6}, Radu Cristian JECAN^{2,4,7}

¹ “Dunărea de Jos” University – Faculty of Medicine and Pharmacy, Galați, Romania

² “Arestetic” Clinic Galați, Romania

³ “Ovidius” University – Faculty of Medicine, Constanța, Romania

⁴ “Carol Davila” University of Medicine and Pharmacy, Bucharest, Romania

⁵ University Emergency Hospital Bucharest, 2nd General Surgery Clinic

⁶ “Bagdasar-Arseni” Clinical Emergency Hospital Bucharest, Department of General Surgery

⁷ Emergency Clinical Hospital “Agrippa Ionescu”, Bucharest, Romania

All authors have equal contributions

Correspondent author: Cristian Constantin Popa, e-mail: cristianconstantinpopa@yahoo.com

Accepted January 23, 2018

Stretch marks are an increasingly common pathology nowadays affecting up to 90% pregnant women, 70% teenagers and 40% sportsmen, creating an unaesthetic appearance of the skin. At the stretch mark level the skin is thinned, soft when touched, with wrinkled surface with high transparency in the case of newly developed stretch (hence their color is red-violet) and white opaque – pearlescent, uneven appearance. Various methods for treating stretch marks have been tried over time, with the most useful proving to be the fractionated laser and fractional radiofrequency. This study shows the results obtained using multipolar fractional radiofrequency with the device 3DEEP Endymed. The results were very good, the assessment being performed by considering the degree of satisfaction of the patient and by directly analysing the appearance of the skin, with immature stretch marks completely disappearing in some cases and the mature ones becoming greatly blurred. Conclusions: The recovery time is short and the risk of burning is low. The results obtained with Endymed 3DEEP are very good with the significant blurring of mature stretch marks and the almost complete disappearance of immature stretch marks. Due to the uniform distribution of energy it does not require overlapping spots. It works on any surface even on the most curved. Due to its matrix on 112 points, it shows a good epidermal effect. The discomfort is minimal.

Key words: stretch marks, radiofrequency, endymed.

INTRODUCTION

Stretch marks take the form of some areas where the skin structure appears as “torn”. Most time they have a genetic component. They affect 90% of pregnant women, 70% of teenagers and 40% of sportsmen. Precisely because of the high incidence of stretch marks during pregnancy there has been attempted the prevention of their occurrence by various methods, but the results were inconclusive^{1, 2, 3}; practically it is the sudden distension of the skin in the last months of pregnancy what causes the tearing of collagen fibres and the appearance of stretch marks.

Radiofrequency is a physical method used for over 20 years in medicine, which can be

unfractional or fractional. Depending on the production mechanism, it can be monopolar, bipolar and multipolar.

The first technologies with radiofrequency (monopolar radiofrequency and then the bipolar one), had the disadvantage of getting either too shallow or too deep into the skin, which often could be painful for the patient and in extreme cases it might even cause superficial burns.

The present study was conducted using a device Endymed 3DEEP. This technology controls efficiently the RF energy to achieve a three-dimensional energy matrix able to treat the target area in depth, which is possible thanks to a sophisticated algorithm, and to a special positioning of electrodes – that by mutual rejection can push the electric fields much deeper, reducing the risk of

affecting the upper layers and eliminating the need for active cooling. We mention that the device presents both unfractional and fractional radiofrequency, this study referring exclusively to fractional radiofrequency. The treatment has aimed at the disappearance or the most possible blurring of the unaesthetic appearance of torn skin in stretch marks area.

MATERIAL AND METHOD

The technique consists in creating certain micro columns with thermal destruction of the skin using radio waves and also in heating the remaining tissues with the effect of contracting the existing collagen fibres and stimulating the production of new ones.

The indications for this study were mature and immature stretch marks. The contraindications were represented by: skin cracks, injury or infection, the presence of metal implants on the treated area, the presence of heart pace-maker or implanted electric defibrillator, the oral concurrent therapy with retinoids, the presence of autoimmune diseases, haematological, neurological or other serious illnesses, recent exposure to sun / solarium during the last month and skin tumours in the area to be treated. Relative contraindications consisted of: pregnancy or lactation, permanent tattoo in the treated area.

The device has 6 levels of power as required. The hand part has a 15 mm × 10 mm applicator with 14 columns × 8 rows. Each pulse is divided into 14 sub-pulses ('clicks'). The matrix is of 300 microns consisting of 112 points.

A month before the treatment the patients should not expose to the sun or solarium. With 10 days before the procedure the administration of anticoagulants, vitamin E, ginkgo biloba, ginseng, omega 3 should be interrupted.

The working technique was the following: the skin is cleaned and a numbing cream is then applied for 30–45 minutes. Then the numbing cream is cleaned and the operating parameters are set. The radiofrequency spots are applied both on stretch marks and on the healthy tissue between the stretch marks that helps to rebuild collagen. Spots do not overlap.

After the procedure a moisturizing cream with a 50% protection factor shall be applied. Cold compresses are recommended in case of discomfort. If there are small scabs, they have to drop themselves, otherwise one can disrupt the normal skin regeneration with the risk of producing scars.

To achieve the optimum effect 3–4 sessions have been recommended at every 4–5 weeks.

After the procedure the following are contraindicated for at least one month: sauna, Jacuzzi, sun exposure, chemical peeling, the use of creams with alpha hydroxy acids (AHA), topical retinoids (Retin A, Isotrexin, Mask gel) or benzoyl peroxide (Brevoxyl).

RESULTS AND DISCUSSIONS

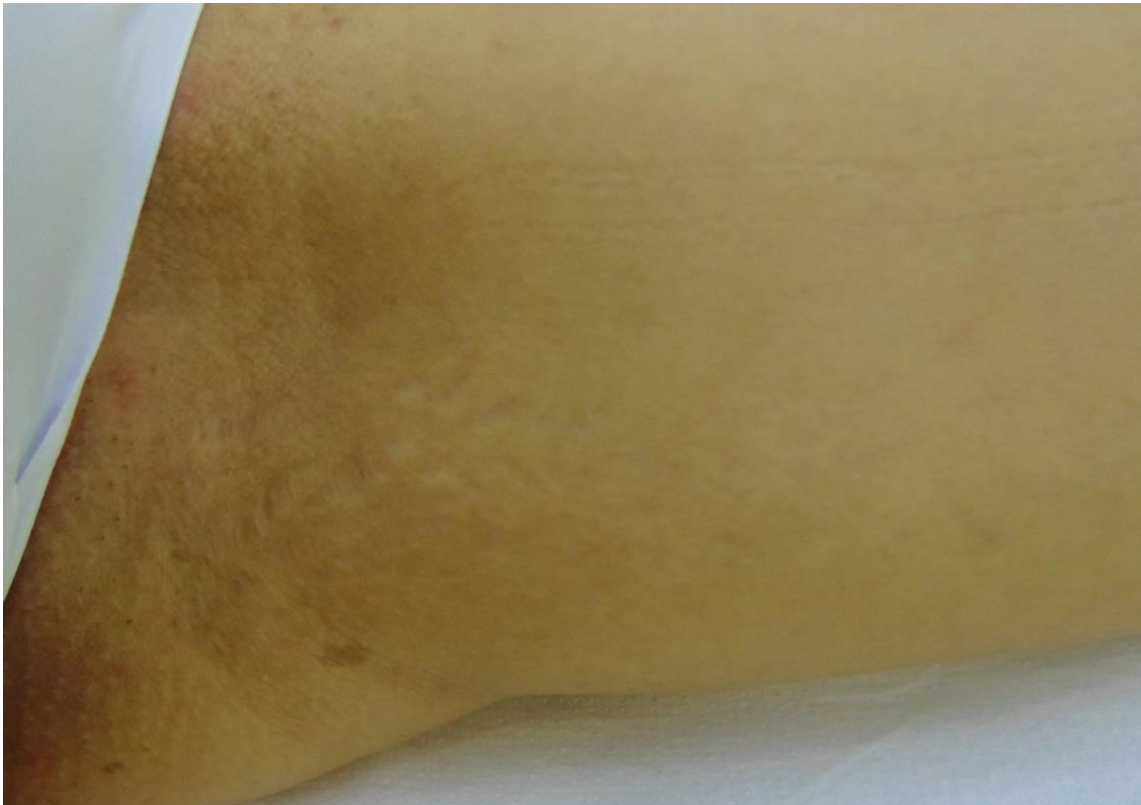
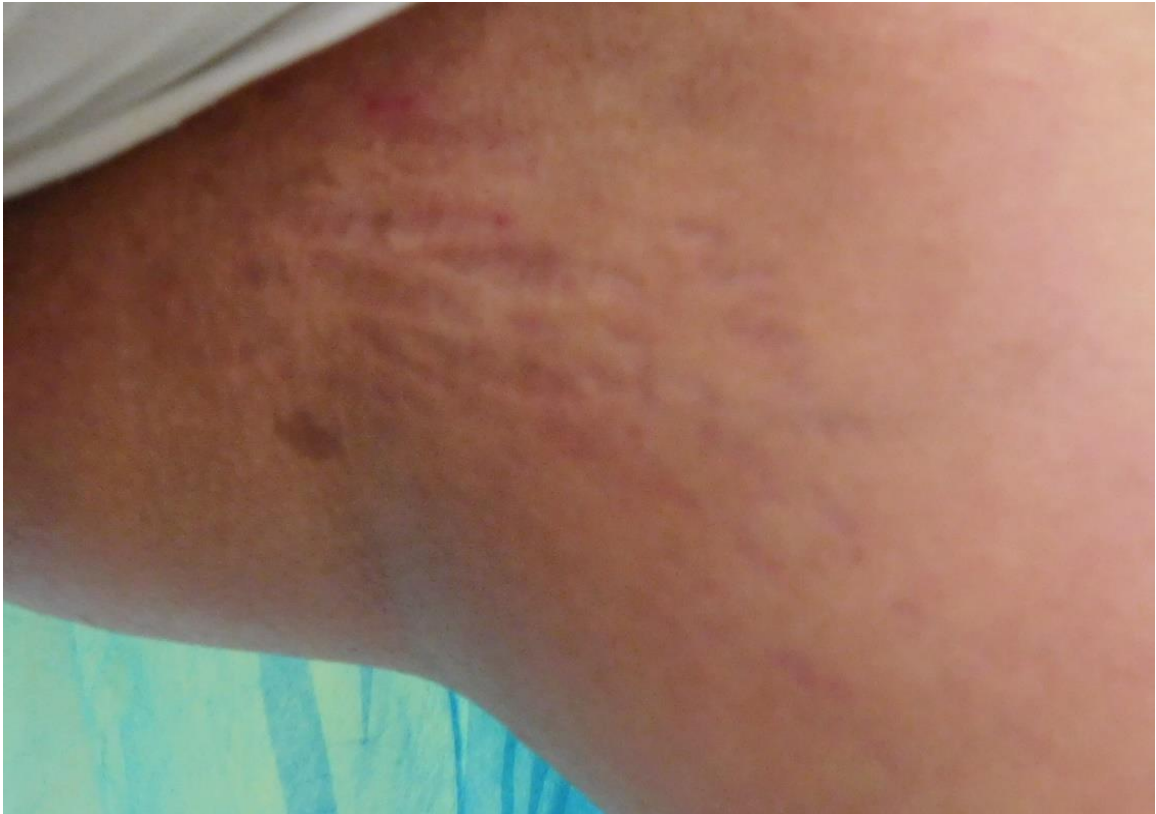The study was performed between 1.01.2016–31.12.2016 in Arestetic Clinic in Galați, on a sample of 16 female patients (Fizpatrick 2–4). The average age was of 31,18 years.

The number of sessions and the intensity used are detailed in Table 1.

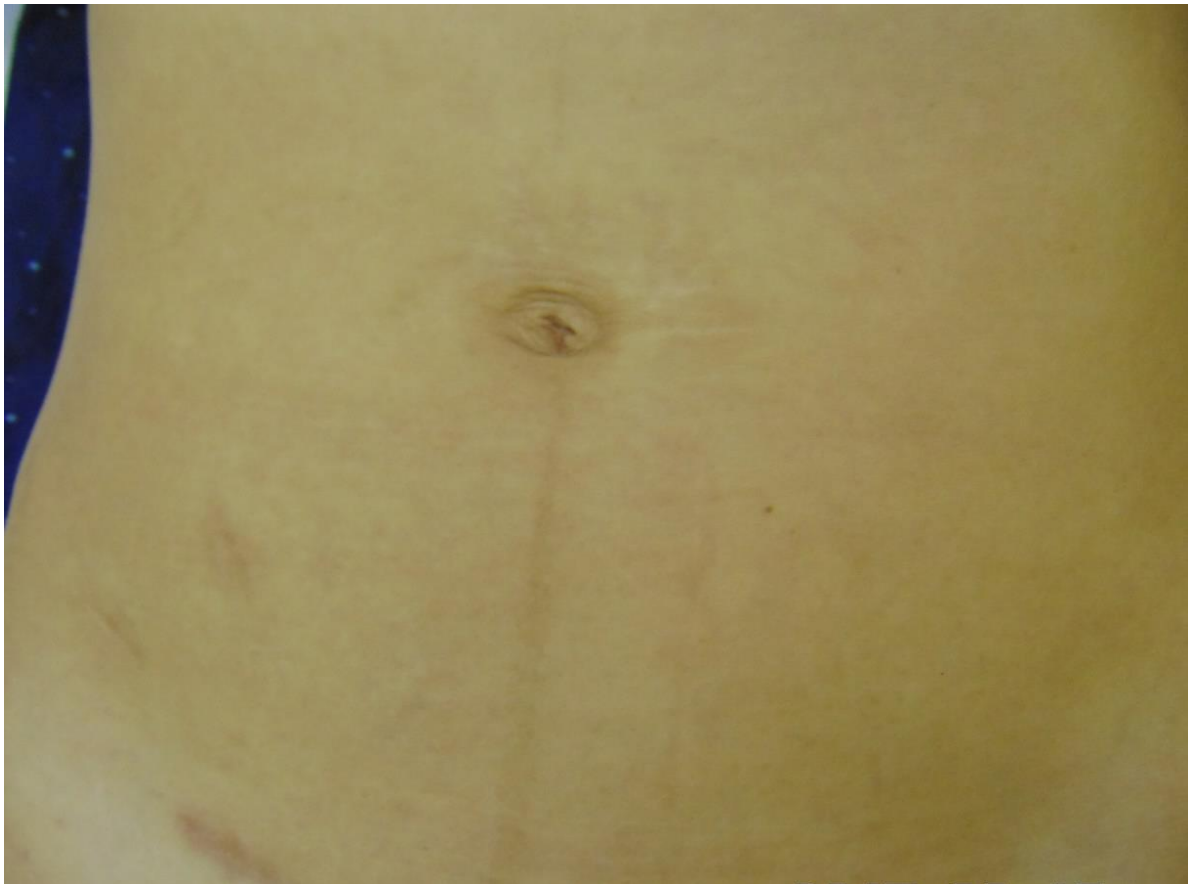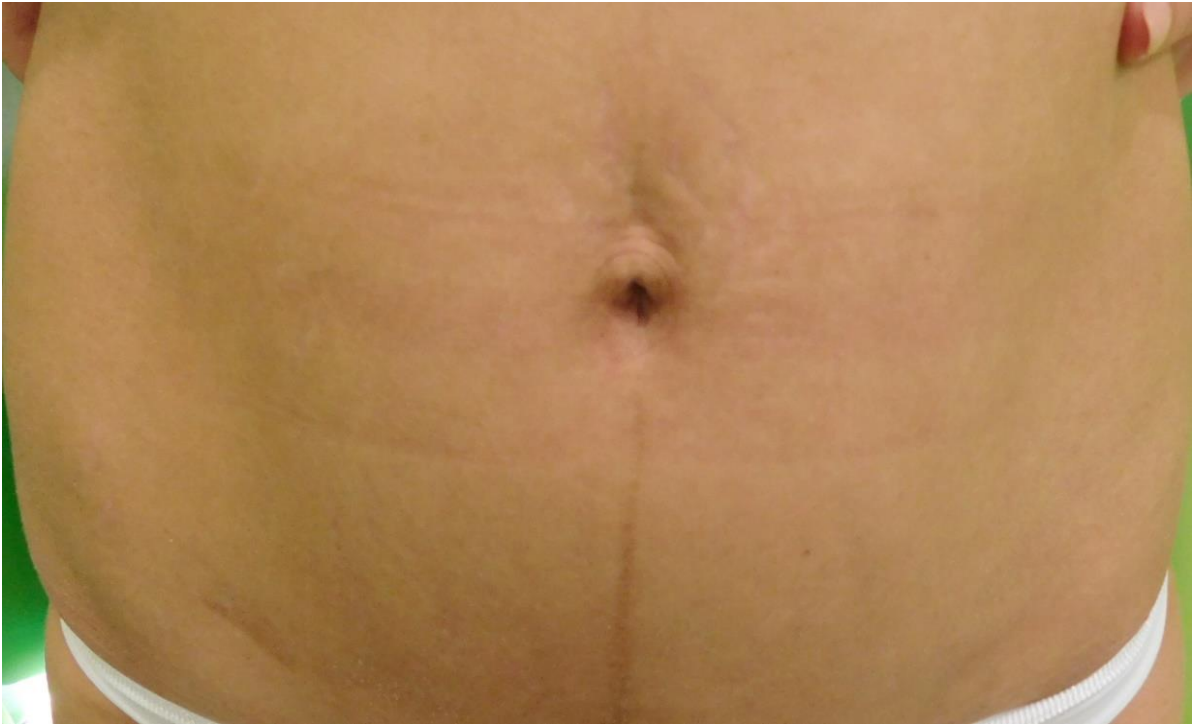Table 1

The distribution of cases

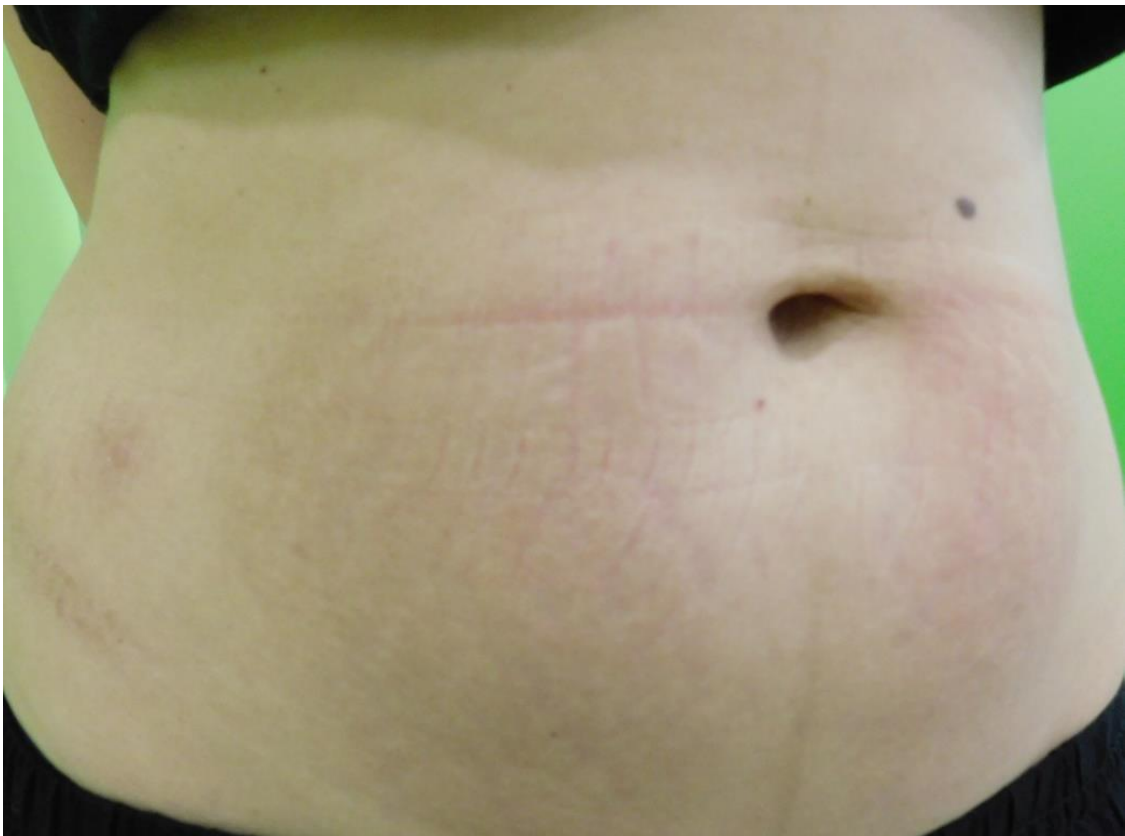
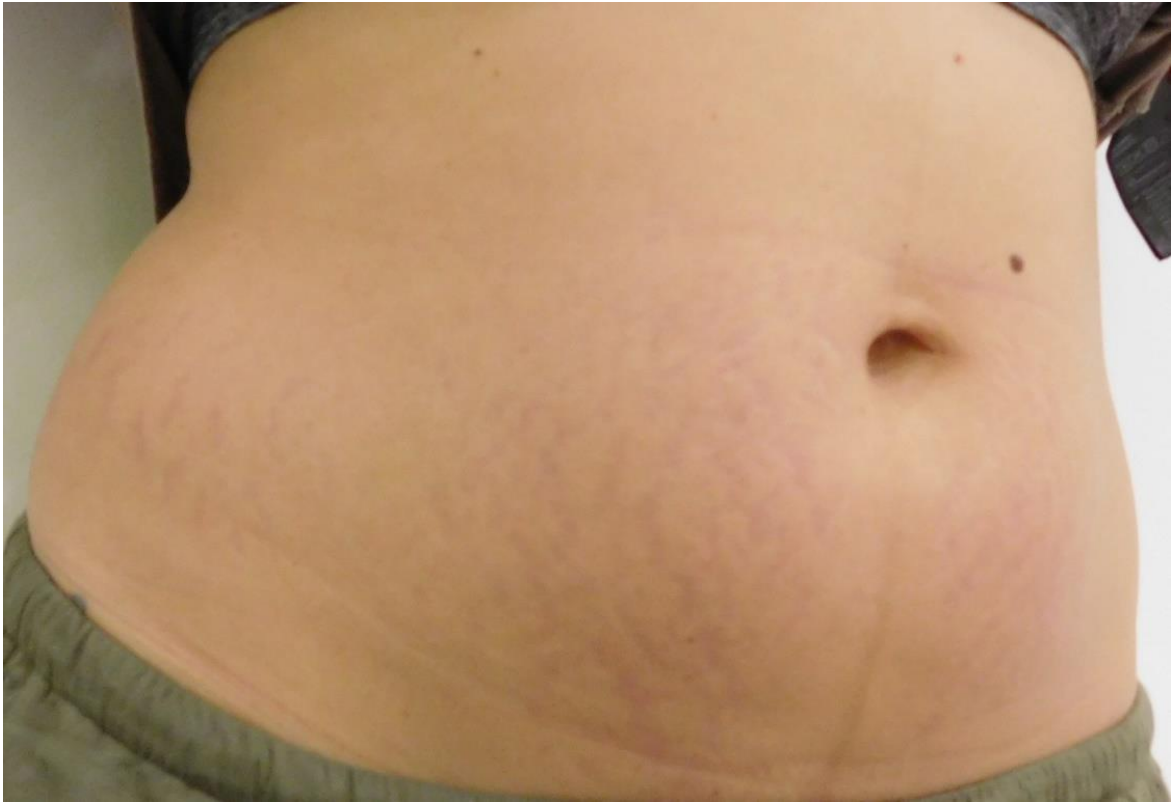Patient	Area of stretch marks	Working intensity	No of sessions	Age	Fizpatrick
1	Abdomen	5	4	31	II
2	Abdomen	5	4	28	IV
3	Abdomen	6	5	35	II
4	Thighs+ calves	5	4	37	IV
5	Buttocks	6	5	21	III
6	Breasts	4	3	23	III
7	Abdomen	6	4	32	II
8	Abdomen	5	4	34	IV
9	Thighs	6	3	29	III
10	Abdomen + breasts	6 (4 on breasts)	3	24	III
11	Buttocks	6	4	30	III
12	Abdomen	5	4	36	II
13	Abdomen	6	4	35	III
14	Abdomen	5	4	29	III
15	Thighs+ arms	4	3	43	IV
16	Abdomen	5	4	34	III



Case 1. Endymed 2 sessions 5th power level.



Case 2. Endymed 3 sessions 6th level.



Case 3. 2 sessions 5th level.

Immediately after the procedure, on the treated area there appeared small pink swellings around the apertures where the micro-needles were located. At a power level above 3 there was noticed the swelling of the whole "square" worked. The swellings and erythema disappeared in 24–48 hours. 1–3 days after the treatment there appeared small dark red dots or pinpoint sized crusts where radiofrequency currents have penetrated. Depending on the skin type, location, issue treated and energy used, these points have persisted 5–14. The swelling and redness after the procedure are normal reactions of the skin and appear on all types of fractional radiofrequency⁴.

In the first 24–48 hours the patients reported a slight burning sensation. Possible side effects include: bruising, post inflammatory hyperpigmentation (especially if the treated area is not protected against the sun), hypopigmentation if skin was tanned, such complications being also cited in the literature in the field⁵.

Results assessment was performed through the quantification of three parameters: colour, width and depth of stretch marks. The colour and depth were subjectively estimated based on comparative photos and direct observation, also taking into account the degree of satisfaction of the patients; colour turned from white-pearly to pinkish, similar to normal skin colour and the depth was reduced almost completely the stretch marks becoming flat, on the same level with the normal skin. The width of stretch marks was estimated by measuring the width of the stretch mark before the treatment and after the last Endymed fractional radiofrequency session. We chose the highest and lowest stretch marks of a certain surface and they were measured. The results showed the reduction in the width of stretch marks with 12 to 19% after the first session and with 23–47% after 4 sessions conducted every month. In case of immature stretch marks, they disappeared after 4 radiofrequency sessions at 69% of the patients treated.

The patients' level of satisfaction was very good, almost all patients have seen major improvements related to the appearance of stretch marks.

In terms of complications, in one case there have been noticed dot shaped burnings on the abdomen and internal thighs area for which we recommended antibiotic creams and healing creams (Stratamark and Nidoflor).

In recent years with the increasing number of breast implants there has been reported an increased incidence of stretch marks on the breasts after

implants⁶. There have been also reported cases of side stretch marks after the installation of skin expanders⁷. Obesity is also increasingly incriminated as a factor favouring the occurrence of stretch marks⁸ the determining mechanism being the same as for pregnancy, the distension of the skin above the extensibility limit of collagen fibres and elastine. Stretch marks have been also associated with Koebner syndrome in association with vitiligo⁹, their treatment in such cases reaching low results or results impossible to be achieved, because of contraindications relating to laser and fractional radiofrequency. Factors favouring the appearance of stretch marks include endocrine imbalances, diet deficient in vitamins and minerals etc.¹⁰.

Radiofrequency has been used for years for treating stretch marks. Initially monopolar radiofrequency¹¹ was used and later with the development of new radiofrequency techniques, bipolar radiofrequency¹² was used. Recently there has been developed a new method for treating mature stretch marks called nano-fractional radio frequency, which works by stimulating the facial remodelling and re-epithelisation of the epidermis¹³. According to the mentioned study 3 sessions were conducted at 4 weeks, so a protocol similar to that of the Endymed fractional radio frequency.

Various methods have been tried over time for the treatment of stretch marks. Combined treatments have been performed with the radio frequency and PRP, for the platelet plasma rich in growing factors to potentiate the recovery of the collagen damaged by radio frequency, superior results being noticed in comparison with the single treatment with radio frequency^{14,15}. Another combination of treatments tested has been the one between fractional radiofrequency and microdermabrasion, in this case microdermabrasion serving to further stimulate the process of neocolagenesis on the surface¹⁶. In this sense there have been produced even comparative studies of effectiveness between PRP and microdermabrasion¹⁷ and between microdermabrasion and local topical treatments¹⁸.

But the most common treatments, either singly or in combination, remain fractional radiofrequency and fractional laser. Very good results have been obtained by combining fractional radiofrequency with CO2 laser^{19,20}, in particular on mature stretch marks. However, there have also been tried other laser wavelengths, such as 1410 nm or 1565 nm^{21,22,23,24}. Very good results have been reported for Erbium laser²⁵ or other fractional lasers. The wavelength of Nd-Yag 1054 Nm has been used to

treat stretch marks, at powers of 75–100 J/cm² with spot of 5 mm and 15 ms duration, with even comparative studies between Nd-Yag and the light intensely pulsed to different wavelengths, but the results are inferior to CO₂ laser or fractional laser^{26, 27}. Recently, there have been attempts to treat stretch marks with intensely pulsed light with different wavelengths respectively of 590 and 650 nm but the results are worse than in case of fractional laser^{28, 29}.

Various local topical have been used as adjuvants for both prevention and treatment, which may increase the effect of radio frequency³⁰. Fractional radio frequency may be combined with chemical peeling, Microneedeling (Dermapen), mesotherapy or carboxytherapy^{26, 31, 32}.

The treatment with Endymed may be associated with other cosmetic procedures as follows:

- After 7 days, injection of botulinum toxin (Botox)
- After 3 weeks, the injection of hyaluronic acid
- 2–3 weeks after the procedure of non-ablative laser or IPL
- After 4–6, chemical peeling
- After 10–12, ablative laser
- 6 months after interruption of the treatment, with oral retinoid.

CONCLUSIONS

The recovery time is short and the risk of burning is low. The results obtained with Endymed 3DEEP are very good with the significant blurring of mature stretch marks and the almost complete disappearance of immature stretch marks. Due to the uniform distribution of energy it does not require overlapping spots. It works on any surface even on the most curved. Due to its matrix on 112 points, it shows a good epidermal effect. The discomfort is minimal.

The colour of stretch marks turned from white-pearly to pinkish, similar to normal skin colour and the depth was reduced almost completely the stretch marks becoming flat, on the same level with the normal skin. The reduction in width of stretch marks was with 12 to 19% after the first session and with 23–47% after 4 sessions conducted every month. In case of immature stretch marks, they disappeared after 4 radiofrequency sessions at 69% of the patients treated.

REFERENCES

1. AO, Yasar Celik E, Tokmak A, Ozler S, Tasci Y. Is it possible to prevent striae gravidarum? *J Chin Med Assoc.* 2016 May; 79(5):272-5. doi: 10.1016/j.jcma.2015.12.007.
2. Atwal GS, Manku LK, Griffiths CE, Polson DW. Striae gravidarum in primiparae. *Br J Dermatol.* 2006; 155:965–9.
3. Taavoni S, Soltanipour F, Haghani H, Ansarian H, Kheirkhah M. Effects of olive oil on striae gravidarum in the second trimester of pregnancy. *Complement Ther Clin Pract.* 2011; 17:167–9.
4. Gold MH, Biesman BS, Taylor M. Enhanced high-energy protocol using a fractional bipolar radiofrequency device combined with bipolar radiofrequency and infrared light for improving facial skin appearance and wrinkles. *J Cosmet Dermatol.* 2017 Feb 8. doi: 10.1111/jocd.12322.
5. Duncan D.I. Complications of Treatment with Radiofrequency in Aesthetic Medicine. *Cosmetic Dermatology.* Aesthet Dermatol. Basel, Karger, 2015, vol. 2, pp. 81-96.
6. Basile FV, Basile AR, Basile A. Striae distensae after breast augmentation: expected findings versus actual findings. *Aesthetic Plast Surg.* 2013 Aug; 37(4):849-50. doi: 10.1007/s00266-013-0144-y.
7. Ergün SS, Ozcan RH, Kural YB. Striae distensae: a rare complication resulting from overinflation of the tissue expander. *Aesthetic Plast Surg.* 2007 Sep-Oct; 31(5):606-7. Epub 2007 Jul 20.
8. Yosipovitch G, DeVore A, Dawn A. Obesity and the skin: skin physiology and skin manifestations of obesity. *J Am Acad Dermatol.* 2007 Jun; 56(6):901-16.
9. Iftikhar N, Rahman A, Janjua SA. Vitiligo appearing in striae distensae as a Koebner phenomenon. *J Coll Physicians Surg Pak.* 2009 Dec; 19(12):796-7.
10. Cho S, Park ES, Lee DH, Li K, Chung JH. Clinical features and risk factors for striae distensae in Korean adolescents. *J Eur Acad Dermatol Venereol.* 2006; 20:1108–13.
11. Nicoletti G, Perugini P, Bellino S, Capra P, Malovini A, Jaber O, Tresoldi M, Faga A. Scar Remodeling with the Association of Monopolar Capacitive Radiofrequency, Electric Stimulation, and Negative Pressure. *Photomed Laser Surg.* 2017 Jan 24. doi: 10.1089/pho.2016.4180.
12. Harmelin Y, Boineau D, Cardot-Leccia N, Fontas E, Bahadoran P, Becker AL, Montaudié H, Castela E, Perrin C, Lacour JP, Passeron T. Fractionated bipolar radiofrequency and bipolar radiofrequency potentiated by infrared light for treating striae: A prospective randomized, comparative trial with objective evaluation. *Lasers Surg Med.* 2016 Mar; 48(3):245-53. doi: 10.1002/lsm.22458. Epub 2016 Jan 12.
13. Pongsrihadulchai N, Chalermchai T, Ophaswongse S, Pongsawat S, Udompataikul M. An efficacy and safety of nanofractional radiofrequency for the treatment of striae alba. *J Cosmet Dermatol.* 2017 Mar; 16(1):84-90.
14. Suh DH, Lee SJ, Lee JH, Kim HJ, Shin MK, Song KY. Treatment of striae distensae combined enhanced penetration platelet-rich plasma and ultrasound after plasma fractional radiofrequency. *J Cosmet Laser Ther.* 2012 Dec; 14(6):272-6.
15. Kim IS, Park KY, Kim BJ, Kim MN, Kim CW, Kim SE. Efficacy of intradermal radiofrequency combined with autologous platelet-rich plasma in striae distensae: a pilot study. *Int J Dermatol.* 2012 Oct; 51(10):1253-8.

16. El-Domyati M, Hosam W, Abdel-Azim E, Abdel-Wahab H, Mohamed E. Microdermabrasion: a clinical, histometric, and histopathologic study. *J Cosmet Dermatol.* 2016 Dec;15(4):503-513
17. Hersant B, Niddam J, Meningaud JP. Comparison between the efficacy and safety of platelet-rich plasma vs microdermabrasion in the treatment of striae distensae: clinical and histopathological study. *J Cosmet Dermatol.* 2016 Dec; 15(4):565.
18. Hessel D, Soirefmann M, Porto MD, Schilling-Souza J, Siega C, Dal'Forno T. Superficial dermabrasion versus topical tretinoin on early striae distensae: a randomized, pilot study. *Dermatol Surg.* 2014 May; 40(5):537-44.
19. Ryu HW, Kim SA, Jung HR, Ryoo YW, Lee KS, Cho JW. Clinical improvement of striae distensae in Korean patients using a combination of fractionated microneedle radiofrequency and fractional carbon dioxide laser. *Dermatol Surg.* 2013 Oct; 39(10):1452-8.
20. Farahnaz Fatemi Naein, Mehrnaz Soghrafi. Fractional CO2 laser as an effective modality in treatment of striae alba in skin types III and IV. *J Res Med Sci.* 2012 Oct; 17(10): 928–933.
21. Wang K, Ross N, Osley K, Sahu J, Saedi N. Evaluation of a 1540-nm and a 1410-nm Nonablative Fractionated Laser for the Treatment of Striae. *Dermatol Surg.* 2016 Feb; 42(2):225-31.
22. Tretti Clementoni M, Lavagno R. A novel 1565 nm non-ablative fractional device for stretch marks: A preliminary report. *J Cosmet Laser Ther.* 2015 Jun; 17(3):148-55.
23. Alves RO, Boin MF, Crocco EI. Striae after topical corticosteroid: Treatment with nonablative fractional laser 1540 nm. *J Cosmet Laser Ther.* 2015 Jun; 17(3):143-7.
24. Tay YK, Kwok C, Tan E. Non-ablative 1,450-nm diode laser treatment of striae distensae. *Lasers Surg Med.* 2006 Mar; 38(3):196-9.
25. Guimarães PA, Haddad A, Sabino Neto M, Lage FC, Ferreira LM. Striae distensae after breast augmentation: treatment using the nonablative fractionated 1550-nm erbium glass laser. *Plast Reconstr Surg.* 2013 Mar; 131(3):636-42.
26. Elsaie ML, Hussein MS, Tawfik AA, Emam HM, Badawi MA, Fawzy MM, Shokeir HA. Comparison of the effectiveness of two fluences using long-pulsed Nd:YAG laser in the treatment of striae distensae. Histological and morphometric evaluation. *Lasers Med Sci.* 2016 Dec; 31(9):1845-1853.
27. Gauglitz GG, Reinholz M, Kaudewitz P, Schaubert J, Ruzicka T. Treatment of striae distensae using an ablative Erbium: YAG fractional laser versus a 585-nm pulsed-dye laser. *J Cosmet Laser Ther.* 2014 Jun; 16(3):117-9.
28. Shokeir H, El Bedewi A, Sayed S, El Khalafawy G. Efficacy of pulsed dye laser versus intense pulsed light in the treatment of striae distensae. *Dermatol Surg.* 2014 Jun; 40(6):632-40;
29. Al-Dhalimi MA, Abo Nasyria AA. A comparative study of the effectiveness of intense pulsed light wavelengths (650 nm vs 590 nm) in the treatment of striae distensae. *J Cosmet Laser Ther.* 2013 Jun; 15(3):120-5.
30. Ud-Din S, McGeorge D, Bayat A. Topical management of striae distensae (stretch marks): prevention and therapy of striae rubrae and albae. *J Eur Acad Dermatol Venereol.* 2016 Feb; 30(2):211-22.
31. Ash K, Lord J, Zukowski M, McDaniel DH. Comparison of topical therapy for striae alba (20% glycolic acid/0.05% tretinoin versus 20% glycolic acid/10% L-ascorbic acid) *Dermatol Surg.* 1998; 24:849–56.
32. Mazzarello V, Farace F, Ena P, Fenu G, Mulas P, Piu L, et al. A superficial texture analysis of 70% glycolic acid topical therapy and striae distensae. *Plast Reconstr Surg.* 2012; 129:589e–90e.